

# PEDIATRIC EMERGENCY MEDICINE PRACTICE

AN EVIDENCE-BASED APPROACH TO PEDIATRIC EMERGENCY MEDICINE ▲ EBMEDICINE.NET

## Pediatric Upper Airway Infectious Disease Emergencies

*During mid-winter in the emergency department, a familiar “barking” sound is heard in the distance. As the sound grows closer, you see a 15-month-old boy being carried by his mother, and you note that he is having difficulty breathing as you follow them into the exam room. While you are observing the child, the parents report that he’s had a fever, cough, and a runny nose for two days. Last night, he developed a deep, harsh quality to his cough, and his breathing has become more labored today. The parents report an unevenful birth and neonatal history, there is no history of similar breathing episodes, and his vaccinations are current. You wonder:*

- What immediate treatment, if any, should be initiated?
- What is this child’s most likely diagnosis?
- What is the best definitive treatment for this child?
- Should you obtain any imaging studies?
- Does this child require hospitalization? How will you decide?

**P**ediatric respiratory emergencies are commonly seen in the emergency department. They can range from mild to severe and, at times, require life-saving interventions to prevent complete airway obstruction and respiratory arrest. Every emergency physician must be able to recognize, assess, stabilize, and manage a pediatric patient with respiratory distress. The presentation of a child in respiratory distress due to an upper airway infection may consist of fever, difficulty breathing, noisy breathing, irritability, and/or dehydration. This issue of *Pediatric Emergency Medicine Practice* discusses the epidemiology, diagnosis, and management of upper airway infectious diseases in children. This article will review the emergency physician’s approach to the assessment, stabilization, and definitive treatment of the following common upper airway

November 2007  
Volume 4, Number 11

### Authors

#### Jennifer Marin, MD

Fellow, Division of Pediatric Emergency Medicine, The Children’s Hospital of Philadelphia, Philadelphia, PA

#### Jill Baren, MD

Associate Professor of Emergency Medicine and Pediatrics, Attending Physician, Emergency Department, Hospital of the University of Pennsylvania and The Children’s Hospital of Philadelphia; Director, Pediatric Emergency Medicine Education, Emergency Medicine Residency, Hospital of the University of Pennsylvania, Philadelphia, PA

### Peer Reviewers

#### Ghazala Q. Sharieff, MD, FAAP, FACEP, FAAEM

Associate Clinical Professor, Children’s Hospital and Health Center/University of California, San Diego; Director of Pediatric Emergency Medicine, California Emergency Physicians, San Diego, CA

#### Joseph Toscano, MD

Attending Physician, San Ramon Regional Medical Center, San Ramon, CA

### CME Objectives

Upon completing this article, you should be able to:

1. Recognize the signs and symptoms of near complete upper airway obstruction.
2. Recognize the broad differential diagnosis of upper airway obstruction in infancy and childhood.
3. List the main anatomic differences between the adult and pediatric airway and how they impact the likelihood of upper airway obstruction in a child.
4. Know procedures that may exacerbate or cause airway obstruction in a child with respiratory distress.
5. Be familiar with the different infectious causes of upper airway obstruction and their clinical presentations.

*Date of original release:* November 1, 2007

*Date of most recent review:* September 14, 2007

*Termination date:* November 1, 2010

*Time to complete activity:* 4 hours

*Medium:* print and online

*Method of participation:* print and online answer form and evaluation

See “Physician CME Information” on back page.

### AAP Sponsor

#### Martin I. Herman, MD, FAAP, FACEP

Professor of Pediatrics, UT College of Medicine, Assistant Director of Emergency Services, Lebonheur Children’s Medical Center, Memphis, TN

### Editorial Board

#### Jeffrey R. Avner, MD, FAAP

Professor of Clinical Pediatrics, Albert Einstein College of Medicine; Chief, Children’s Emergency services, Children’s Hospital at Montefiore, Bronx, NY

#### T. Kent Denmark, MD, FAAP, FACEP

Residency Director, Pediatric Emergency Medicine; Assistant Professor of Emergency Medicine and Pediatrics, Loma Linda University Medical Center and Children’s Hospital, Loma Linda, CA

#### Michael J. Gerardi, MD, FAAP, FACEP

Clinical Assistant Professor, Medicine, University of Medicine and Dentistry of New Jersey; Director, Pediatric Emergency Medicine, Children’s Medical Center, Atlantic Health System; Department of Emergency Medicine, Morristown Memorial Hospital, Morristown, NJ

#### Ran D. Goldman, MD

Associate Professor, Department of Pediatrics, University of Toronto; Division of Pediatric Emergency Medicine and Clinical Pharmacology and Toxicology, The Hospital for Sick Children, Toronto, ON

#### Mark A. Hostetler, MD, MPH

Assistant Professor, Department of Pediatrics; Chief, Section of Emergency Medicine; Medical Director, Pediatric Emergency Department, The University of Chicago, Pritzker School of

Medicine, Chicago, IL

#### Alison S. Inaba, MD, FAAP, PALS-NF

Pediatric Emergency Medicine Attending Physician, Kapiolani Medical Center for Women & Children; Associate Professor of Pediatrics, University of Hawaii John A. Burns School of Medicine, Honolulu, HI; Pediatric Advanced Life Support National Faculty Representative, American Heart Association, Hawaii & Pacific Island Region

#### Andy Jagoda, MD, FACEP

Vice-Chair of Academic Affairs, Department of Emergency Medicine; Residency Program Director; Director, International Studies Program, Mount Sinai School of Medicine, New York, NY

#### Tommy Y. Kim, MD, FAAP

Attending Physician, Pediatric Emergency Department; Assistant

Professor of Emergency Medicine and Pediatrics, Loma Linda Medical Center and Children’s Hospital, Loma Linda, CA

#### Brent R. King, MD, FACEP, FAAP, FAAEM

Professor of Emergency Medicine and Pediatrics; Chairman, Department of Emergency Medicine, The University of Texas Houston Medical School, Houston, TX

#### Robert Lutén, MD

Professor, Pediatrics and Emergency Medicine, University of Florida, Jacksonville, FL

#### Ghazala Q. Sharieff, MD, FAAP, FACEP, FAAEM

Associate Clinical Professor, Children’s Hospital and Health Center/University of California, San Diego; Director of Pediatric Emergency Medicine, California Emergency Physicians, San Diego, CA

#### Gary R. Strange, MD, MA, FACEP

Professor and Head, Department of Emergency Medicine, University of Illinois, Chicago, IL

#### Adam Vella, MD, FAAP

Assistant Professor of Emergency Medicine, Pediatric EM Fellowship Director, Mount Sinai School of Medicine, New York

#### Michael Witt, MD, MPH, FAAP

Attending Physician, Division of Emergency Medicine, Children’s Hospital Boston; Instructor of Pediatrics, Harvard Medical School, Boston, MA

### Research Editor

#### Christopher Strother, MD

Fellow, Pediatric Emergency Medicine, Mt. Sinai School of Medicine; Chair, AAP Section on Residents, New York, NY

**Accreditation:** This activity has been planned and implemented in accordance with the Essentials and Standards of the Accreditation Council for Continuing Medical Education (ACCME) through the joint sponsorship of Mount Sinai School of Medicine and *Pediatric Emergency Medicine Practice*. The Mount Sinai School of Medicine is accredited by the ACCME to provide continuing medical education for physicians. **Faculty Disclosure:** Dr. Baren, Dr. Marin, Dr. Sharieff, and Dr. Toscano report no significant financial interest or other relationship with the manufacturer(s) of any commercial product(s) discussed in this educational presentation. **Commercial Support:** *Pediatric Emergency Medicine Practice* does not accept any commercial support.

infections: croup, bacterial tracheitis, retropharyngeal abscess, peritonsillar abscess, and epiglottitis.

A number of changes have begun to take place in the management of these illnesses. Historically, humidified mist was used as initial therapy for children with croup, although its effectiveness was never proven. Recent studies have confirmed no benefit from this therapy.<sup>13,14</sup> Retropharyngeal and peritonsillar abscesses, previously thought to be amenable only to surgical drainage, have now been shown to respond to aggressive medical therapy alone in certain cases.<sup>15-19</sup> Finally, ultrasound as an imaging tool for use in the evaluation of upper airway pathology<sup>20-24</sup> may provide a less costly and more rapid option for diagnosis that does not cause radiation exposure (to which developing children are particularly sensitive).

## Epidemiology And Etiology

Studies of upper airway infectious diseases span the pediatric, emergency medicine, and otolaryngology literature. The focus is on patient demographics, diagnostic approaches, medical and surgical treatment options, and the changing epidemiology of certain diseases based on current immunization recommendations. With the introduction of the *Haemophilus influenzae* type b (HIB) vaccine in the late 1980s and the approval of the 7-valent pneumococcal vaccine (PCV-7, Prevnar®) in 2000, there has been a change in the epidemiology and bacteriology of many infectious diseases. In particular, epiglottitis, previously caused almost exclusively by HIB, was thought to be virtually eliminated in children. More recent studies and case series describe the prevalence of epiglottitis as well as new and different bacteriologic profiles.<sup>1-6</sup> Furthermore, there is a documented rise in the incidence of epiglottitis in adults.<sup>7-12</sup>

## Anatomy

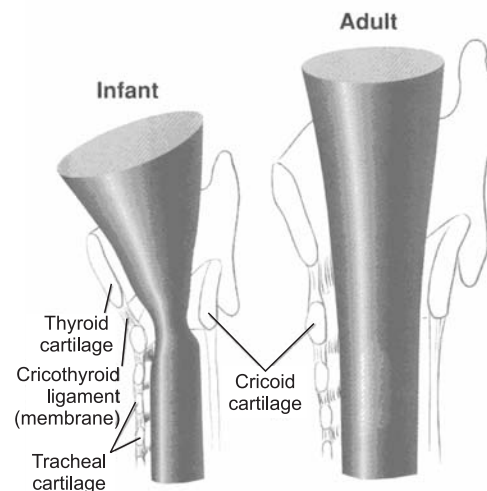
There are striking and important anatomical differences between the pediatric and adult airways which result in greater susceptibility of children to upper airway obstruction, see **Table 1** and **Figure 1**. Young children have disproportionately large heads and tongues and poor cervical spine support.<sup>25</sup> This may lead to airway obstruction from the tongue and the anterior pharyngeal tissue lying against the posterior wall of the hypopharynx when the child is positioned flat on a stretcher. The narrowest point in a child's airway is the subglottic region (whereas the level of the vocal cords is the narrowest in adults); this has been the reason for the traditional use of an uncuffed

endotracheal tube in small children. Surrounded entirely by cricoid cartilage, this area of the pediatric airway is restricted in its ability to expand in diameter.<sup>25</sup> All of these factors make a child more susceptible to airway obstruction, given the same degree of inflammation. A reduction in the diameter of the pediatric airway results in a significant increase in airflow resistance,<sup>26</sup> as demonstrated by this simplification of Poiseuille's law: Resistance = 1/radius.<sup>4</sup>

**Table 1. Differences Between The Pediatric And Adult Airway**

- Disproportionally larger heads
- Disproportionally bigger tongues
- The narrowest region is the subglottic airway
- Poor cervical spine support
- The epiglottis is more floppy and U-shaped
- The larynx is more anterior and cephalad
- Smaller tracheal length

**Figure 1. Comparison Of Infant And Adult Airway**



From: Henretig, et al. *Textbook of Pediatric Emergency Procedures*

## Pathophysiology

With airway obstruction comes turbulent air flow through the large airways. Depending on the degree of the obstruction, stridor may be heard. Stridor is an intense, harsh sound that originates from the extrathoracic airway (from the hypopharynx just above the vocal cords down the trachea to the level of the thoracic inlet). Often, stridor can be heard without the aid of a stethoscope, but listening with a stethoscope just outside the patient's mouth may help to differentiate stridor from other adventitious breath sounds in the chest. Stridor is typically an inspiratory sound if originating from the extrathoracic trachea.<sup>27</sup> Biphasic stridor (that which occurs during both the inspiratory and expiratory phases of

respiration) indicates severe obstruction and is a sign of disease progression.<sup>28</sup>

## Differential Diagnosis

There are many causes of upper airway obstruction so it is helpful to divide them into infectious and non-infectious etiologies, see **Table 2**. The timing of onset of symptoms and the presence of fever will help to distinguish infectious from non-infectious causes. Symptoms from non-infectious conditions (typically congenital abnormalities) often present at birth but may develop over time or even be acquired. Infants born with a laryngeal web, vocal cord paralysis, or a large cystic hygroma manifest stridor at birth. In contrast, stridor due to laryngomalacia is first heard at about four to six weeks of age with resolution by 18-24 months. Angioedema, foreign body aspiration, and foreign body ingestion, which cause anterior displacement of the esophagus producing “posterior compression” of the trachea, are examples of acquired causes of stridor. Subglottic stenosis is an example of a lesion that may present with stridor at birth but may also be acquired from post-endotracheal intubation inflammation. Most importantly, a superimposed infectious process

**Table 2. Differential Diagnosis Of Stridor**

### **Infectious**

Croup  
Epiglottitis  
Tracheitis  
Retropharyngeal abscess

### **Non-infectious**

#### **Symptoms at birth**

Laryngeal web  
Vocal cord paralysis  
Cystic hygroma  
Subglottic stenosis

#### **Symptoms after neonatal period**

Subglottic hemangioma  
Laryngeal papilloma  
Laryngomalacia  
Tracheomalacia  
Vascular ring/sling

#### **Acquired**

Foreign body aspiration  
Foreign body ingestion  
Spasmodic croup  
Laryngospasm  
Psychogenic stridor  
Angioedema  
Paratracheal mass (teratoma, lymphoma)  
Vocal cord paralysis (secondary to intubation)  
Subglottic stenosis (secondary to intubation)

(such as a common viral infection) can worsen the baseline upper airway obstruction due to a non-infectious cause, such as an anatomic abnormality.

## Prehospital Care

Prehospital providers must be skilled in the evaluation and management of a child with upper airway obstruction. Given the potential for complete airway obstruction in a patient with a partial obstruction, it is paramount to avoid any further agitation of a child in respiratory distress. Children will place themselves in the position of greatest comfort, one which allows maximal air entry around the obstruction. If the child is spontaneously breathing, oxygen should be applied if it does not cause agitation.<sup>25</sup> These children must be transported to the nearest medical facility. It is prudent not to delay emergency care in order to transport a child to a tertiary care hospital. The nearest facility can stabilize the patient prior to transfer, if transfer is deemed necessary and safe. Prehospital protocols for definitive treatment of children in respiratory distress depend on the scope of the provider; some prehospital providers are trained in advanced airway techniques, while others are equipped to provide basic life support.

## ED Evaluation

First, determine if the child is stable or unstable by observation. A stable patient allows time to obtain a careful and detailed history from caregivers and prehospital personnel. The unstable or severely ill child warrants immediate intervention while taking a cursory history.

The history (**Table 3**) from parents or guardians is key in deciphering if the child’s distress is secondary to an infectious or non-infectious etiology. Prehospital caregivers have insight into the severity of the illness by relaying their initial impressions of

**Table 3. Important Historical Questions For A Child With Upper Airway Distress**

1. Presence, height, and duration of fever
2. Upper respiratory tract symptoms (rhinorrhea, presence and quality of cough)
3. Description of airway noises and whether inspiratory or expiratory
4. Voice changes, hoarseness
5. Timing of symptoms and relationship to feeding
6. Foreign body exposures (older siblings in the home)
7. Sick contacts
8. Day care exposure
9. Vaccinations

the child (including vital signs) when the child was en route to the hospital.

Begin the physical exam noting all vital signs, including pulse oximetry. Take care to initially perform as much of the exam as possible from afar by simply observing the child's position of comfort. Watch and listen to the child breathe without a stethoscope. As stated earlier, the child with inspiratory stridor at rest or biphasic stridor already has some degree of airway obstruction that can progress to complete obstruction with time. The intraoral exam should be deferred (Table 4) as this may lead to local trauma, agitation, and emotional distress<sup>25,29</sup> which all have the potential to worsen a partial upper airway obstruction. See Table 5 for a comparison of infectious upper airway emergencies.

## Overview, Diagnostic Approach, And Treatment

### Croup (Table 5)

#### Overview

Croup, or laryngotracheobronchitis, is the most common cause of acute stridor in childhood.<sup>13,30</sup> About 3-5% of children less than six years of age have croup, but less than 5% of those will require hospitalization.<sup>13,31</sup> The most common infectious etiology is parainfluenza types 1 and 2, but other causes include influenza viruses A and B, respiratory syncytial virus, rhinovirus, *Mycoplasma pneumoniae*, herpes simplex type I, measles, adenovirus, and varicella; numerous other organisms have also been reported as causes of croup.<sup>32</sup> Croup may be seen throughout the year;

**Table 4: Procedures And Maneuvers To Avoid In The Child With Severe Upper Airway Distress**

1. Intraoral exam
2. Intravenous catheter placement
3. Intramuscular shots
4. Repositioning (patient should rest in the position that is most comfortable for them)

**Table 5: Comparison Of Infectious Upper Airway Emergencies**

	Average Age	Common Etiology	Medications
<b>Croup</b>	Six months to six years	Parainfluenzae	Dexamethasone +/- racemic epinephrine
<b>Bacterial Tracheitis</b>	Four to six years	<i>S. aureus</i>	Antibiotics IV
<b>RPA*</b>	Three years	GABHS#, <i>S. aureus</i> , anaerobes	Antibiotics IV
<b>PTA^</b>	Adolescence	GABHS#	Antibiotics PO vs. IV
<b>Epiglottitis</b>	Two to eight years	<i>H. influenzae</i> , <i>Staphylococci</i> , <i>Streptococcus</i> species	Antibiotics IV

\* Retropharyngeal abscess ^Peritonsillar abscess #Group A beta-hemolytic streptococcus

however, most cases occur in the fall and winter months.<sup>25</sup> Croup is seen in children as young as six months to about six years of age,<sup>14</sup> with a peak incidence in the second year of life.<sup>33</sup>

Symptoms at the onset of illness are usually consistent with a simple upper respiratory infection (low-grade fever, rhinorrhea, cough). The illness then progresses to signs and symptoms consistent with upper airway edema (barking cough, inspiratory stridor, hoarseness)<sup>34</sup> and respiratory distress (retractions may be present). The length of the illness can be from three to seven days. Breath sounds are generally clear, although the sound of upper airway congestion may be transmitted to the chest. Symptoms are often worse at night and are exacerbated by agitation and crying. Beware of diagnosing simple, uncomplicated croup in a very young child (less than six months) or in those with recurrent or severe symptoms not responding to traditional therapy.<sup>35</sup> In these patients, an aggressive search for another etiology of stridor is warranted because of the broad differential diagnosis in that age group. As mentioned earlier, biphasic stridor is an indication of severe airway obstruction; alone or in conjunction with retractions, severe tachypnea or oxygen desaturation should alert the physician to impending respiratory failure.<sup>28</sup> Scoring systems for the assessment of the degree of respiratory distress in a child with croup have proven useful in research settings. The most common of these is the Westley croup score. Emergency physicians should be familiar with the Westley croup score so they can evaluate the literature appropriately, but this score has little role in clinical practice,<sup>36</sup> see Table 6.

#### Diagnosis

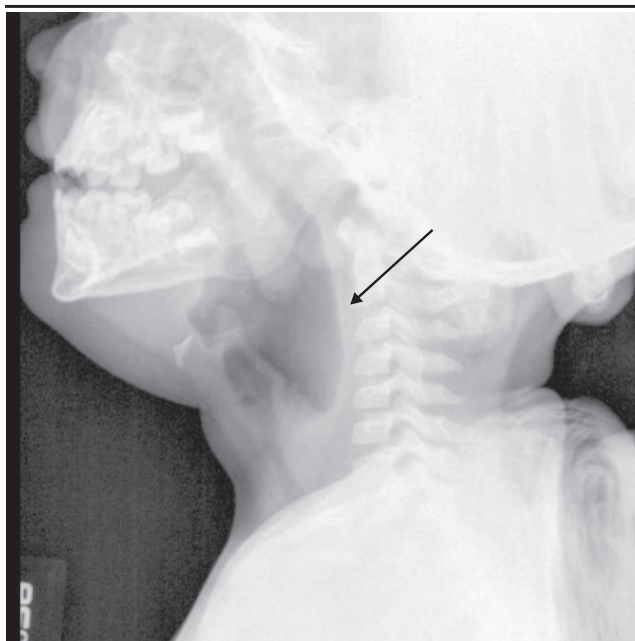
Croup is a clinical diagnosis and does not require confirmation by ancillary testing. When other diagnoses (such as a foreign body or epiglottitis) need to be ruled out, posterior-anterior (PA) and lateral x-rays of the neck may be helpful, see Table 7. The

classic radiographic finding in a child with croup is a narrowed subglottic region of the trachea; this is commonly referred to as a “steeple sign” on the PA view, see **Figures 2 and 3**. Radiographic findings may be absent in as many as 50% of patients with croup.<sup>28,37,38</sup> Laboratory studies are unnecessary; if obtained, the complete blood count may show a leukocytosis with a lymphocytic predominance. However, a normal white blood cell count is common.<sup>25</sup>

### Treatment

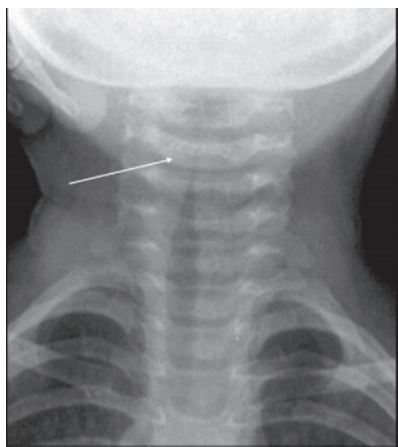
Croup is a self-limited illness that generally only

**Figure 2. Croup. Overdistension Of Hypopharynx**



Reprinted with permission from: [http://rad.usuhs.edu/medpix/medpix.html?mode=caption\\_search&srchstr=Retropharyngeal+AND+Abscess&srch%20type=any&action=search](http://rad.usuhs.edu/medpix/medpix.html?mode=caption_search&srchstr=Retropharyngeal+AND+Abscess&srch%20type=any&action=search)

**Figure 3. AP XR Showing Croup**



Note the narrowing of the trachea at the glottis, refer to the “steeple sign”.

Reprinted with permission from: [http://rad.usuhs.edu/medpix/medpix.html?mode=caption\\_search&srchstr=Retropharyngeal+AND+Abscess&srch%20type=any&action=search](http://rad.usuhs.edu/medpix/medpix.html?mode=caption_search&srchstr=Retropharyngeal+AND+Abscess&srch%20type=any&action=search)

requires treatment with systemic steroids. In more moderate to severe cases, the combination of racemic epinephrine and steroids or intubation and mechanical ventilatory support may be required, but this is uncommon.

Historically, patients with croup were initially treated with humidified air from a humidifier or a

**Table 6: Westley Croup Scoring System**

<b>Stridor</b>	
None	0
Audible with stethoscope (at rest)	1
Audible without stethoscope (at rest)	2
<b>Retractions</b>	
None	0
Mild	1
Moderate	2
Severe	3
<b>Air entry</b>	
Normal	0
Decreased	1
Severely decreased	2
<b>Cyanosis</b>	
None	0
With agitation	1
At rest	2
<b>Level of consciousness</b>	
Normal	0
Altered	5

Reprinted with permission from: Westley CR, Cotton EK, Brooks JG. Nebulized racemic epinephrine by IPPB for the treatment of croup. *Am J Dis Child* 1978;132:484-487.

**Table 7: Radiographic Findings In Children With Upper Airway Infections**

	<b>Imaging</b>	<b>Findings</b>
Croup	X-ray PA* neck	"Steeple sign" (subglottic airway narrowing)
Bacterial tracheitis	X-ray PA neck	"Steeple sign"
	X-ray lateral neck	Pseudomembrane detachment
Retropharyngeal abscess	X-ray lateral neck	Widened retropharyngeal space
	CT neck with contrast	Rim-enhancing mass
Peritonsillar abscess	CT neck with contrast	Rim-enhancing mass
	Intraoral ultrasound	Enlarged tonsil with adjacent heterogeneous or cystic appearance
Epiglottitis	X-ray lateral neck	"Thumbprint sign" (thickened epiglottis)

\*Postero-anterior

steam shower.<sup>28</sup> This was based on the presumption that inflamed mucosa would be soothed by the mist and that secretions would be liquefied, allowing for easier expectoration.<sup>28</sup> Recently, published trials questioned this presumption by evaluating the efficacy of mist in the treatment of croup.<sup>13,14</sup> The first study by Neto et al randomized 71 children with moderate croup to receive either humidified oxygen via a mist stick or no mist.<sup>14</sup> The authors found no difference in the change in croup scores or vital signs between groups. A second study evaluated the difference in the Westley croup score in three groups of patients with moderate to severe croup. The groups were given either blow-by humidity (which is equivalent to inspired room air and represents current standard of care), controlled delivery of 40% humidity, or 100% humidity.<sup>13</sup> This study also failed to show a difference between the three modes of mist delivery and concluded that humidity was not helpful for the treatment of moderate croup in the ED. The Cochrane Collaboration review of randomized controlled trials concluded that croup scores are not greatly improved with the use of humidified air.<sup>33</sup>

Systemic steroids have been shown to be beneficial in the management of children presenting to the ED with mild, moderate, or severe croup.<sup>39-43</sup> Steroids reduce submucosal edema and decrease the inflammatory reaction to the infectious agents which cause croup.<sup>28</sup> Although the side effects of short-term steroid use are rare, there are documented complications of oral candidiasis and bacterial tracheitis.<sup>28</sup> Studies have shown a reduction in both hospital admission and symptoms of airway obstruction as rapid as one hour after treatment.<sup>41</sup> Oral dexamethasone has been shown to be as effective as intramuscular dexamethasone<sup>44</sup> and is the preferred route of administration in children in order to limit pain and anxiety. Two recent studies have shown that 0.15 mg/kg of PO or IV dexamethasone is as effective as 0.6 mg/kg.<sup>41,45</sup> Dexamethasone is widely accepted as the steroid of choice for the treatment of croup because of its long half-life and duration of action. Dexamethasone is a glucocorticoid which is five to six times as potent as prednisolone.<sup>46,47</sup> The half-life of dexamethasone is between 36 and 72 hours, whereas the half-life of prednisolone is 12-36 hours.<sup>47</sup> One study compared the two drugs in single oral dosing for the treatment of mild to moderate croup and found that dexamethasone was more effective in preventing subsequent unscheduled medical care visits.<sup>34</sup> Given the differences in half life, this finding is not surprising. A study of two to three doses of pred-

nisolone compared to a single dose of dexamethasone is needed to adequately compare the two drugs. Dexamethasone has been extensively studied in the management of croup and is associated with a significantly lower rate of return visits and quicker resolution of symptoms compared to placebo, even in children with mild croup. Therefore, it should be given to all children who present to the ED with croup.<sup>42</sup>

Given the strong evidence in favor of systemic steroids, it is reasonable to consider the use of inhaled glucocorticoids which target the affected organ system and, theoretically, result in less systemic side effects. Three studies have looked at the role of budesonide in the treatment of croup.<sup>48-50</sup> All showed a benefit of inhaled budesonide (either alone or in combination with dexamethasone) compared to placebo, but no study has ever demonstrated inhaled budesonide to be superior to dexamethasone for the treatment of croup.

Nebulized racemic epinephrine is an important medication for the treatment of moderate to severe croup. It's vasoconstrictive, alpha-adrenergic effect on the mucosal vasculature is highly effective in reducing airway edema.<sup>36,51,52</sup> Its effects are rapid, with improvement in clinical status within 10-30 minutes;<sup>53</sup> however, its effects are also transient and disappear within two hours of administration.<sup>36,51,52</sup> Historical concern for rebound airway edema after administration of racemic epinephrine has been refuted based on studies which found that patients may be safely discharged from the ED after a two to three hour period of observation if they remain free of stridor at rest and show no signs of respiratory distress.<sup>54-56</sup> Racemic epinephrine should be administered to patients with stridor at rest as an immediate therapy while systemic steroids begin to take effect. This intervention may obviate the need for admission in a child with moderate croup. The following dosing recommendation is used at our institution: racemic epinephrine as a 2.25% mixture. Volume is weight-based: 0.25 mL (5 - 10 kg), 0.5 mL (10 - 20 kg), 1cc (> 20 kg). If racemic epinephrine is not available, administer 5 mL of 1:1000 epinephrine in a nebulizer.

Heliox is a gas mixture of helium and oxygen that has been shown to be of benefit in the treatment of selected patients with severe croup.<sup>57</sup> With a gas density much lower than that of room air or oxygen alone, heliox reduces turbulent flow in the airways and around the obstruction, resulting in decreased work of breathing.<sup>57</sup> Heliox mixture is effective with ratios of 80:20 and 60:40 parts of helium:oxygen. Consequently, it cannot be used in patients who have

a supplemental oxygen requirement beyond 40%.

Although rare, a small percentage (2%) of hospitalized patients with croup ultimately require intubation to gain control of their airway.<sup>58</sup> For information about advanced airway management, see the January 2006, Volume 3 Number 1 *Pediatric Emergency Medicine Practice* article, "Managing the Pediatric Airway in the ED," available at no cost to subscribers at <http://pediatric.ebmedicine.net/redirect>.

## Bacterial Tracheitis (Table 5)

### Overview

Bacterial tracheitis is a rare bacterial airway infection that is also known as bacterial laryngotracheobronchitis, membranous laryngotracheobronchitis, and pseudomembranous croup.<sup>28</sup> In a recent retrospective, descriptive case series of 107 children hospitalized between 1997-2006 with various upper respiratory illnesses, two had epiglottitis and 18 had bacterial tracheitis. Of those with bacterial tracheitis, 15 were intubated and five had serious complications such as ARDS and multisystem organ failure. Bacterial tracheitis was three times more likely to have caused respiratory failure than viral croup and epiglottitis combined and, therefore, should be considered in all children who present with an acute, life-threatening upper respiratory infection.<sup>59</sup> Similarly, a 2005 case series of 12 patients diagnosed with bacterial tracheitis between 1992 and 2004 found bacterial tracheitis to be a considerable cause of severe infectious upper airway obstructions. All children were intubated and four developed complications from illness.<sup>60</sup>

Usually seen in the fall and winter months,<sup>61,62</sup> bacterial tracheitis affects children six months to eight years of age, although the average age of patients is four to six years. Compared to children with viral croup, children with bacterial tracheitis are generally older, more ill appearing, and rarely respond to racemic epinephrine.<sup>61,62</sup> Compared to children with epiglottitis, patients with bacterial tracheitis have a significant cough, are comfortable when lying flat, and tend not to drool.<sup>62</sup> The most common organism responsible for bacterial tracheitis is *Staphylococcus aureus*. Other organisms that have been implicated include HIB, alpha-hemolytic *Streptococcus*, pneumococcus, group A *Streptococcus*, and *Moraxella catarrhalis*.<sup>28,61-63</sup> The clinical picture begins with several days of fever, cough, and stridor, resembling that of viral croup. Children then progress to rapid onset of high fever, difficulty breathing, and an ill appearance.

### Diagnosis

Anteroposterior radiographs of the airway/soft tissues of the neck may show the classic "steep sign" noted with croup, see **Table 7**. On the lateral view, there is a diffusely hazy tracheal air column with multiple luminal soft tissue irregularities indicative of pseudomembrane detachment.<sup>64</sup>

### Treatment

Once the diagnosis of bacterial tracheitis is considered, broad-spectrum antibiotics should be administered. Options for treatment include vancomycin for methicillin-resistant *Staphylococcus aureus* (MRSA) or a semisynthetic penicillin (such as oxacillin) combined with a third-generation cephalosporin (such as ceftriaxone or cefotaxime), see **Table 8**.<sup>25,28</sup> Advanced airway management should not be delayed in the ill-appearing child. A tube size at least one size smaller than recommended is necessary due to the large amount of purulent secretions and narrowed airway diameter. All patients with suspected bacterial tracheitis should be admitted to the hospital for observation in the intensive care unit. Patients should not be sent out of the department for x-rays.

**Table 8: Pediatric Dosing For Antibiotics In Upper Airway Infections\***

<b>PO</b>	
Amoxicillin/clavulanic acid	90 mg/kg/d divided BID (max 875 mg/dose)
Clindamycin	25 mg/kg/d divided TID (max 450 mg/dose)
<b>IV</b>	
Ampicillin/sulbactam	100 mg/kg/d divided Q6 hours (max 8 g/d)
Clindamycin	40 mg/kg/d divided Q8 hours (max 2.7 g/d)
Cefotaxime	120 mg/kg/d divided Q8 hours (max 2 g Q8)
Ceftriaxone	50 mg/kg/d Q24 hours (max 2 g/d)
Vancomycin	10 mg/kg Q6 hours (max 2 g/d)
Oxacillin	150 mg/kg/d divided Q6 hours (max 8 g/d)

\*Doses are from The Children's Hospital of Philadelphia Formulary (Pharmacy Handbook Formulary, 2006, Lexi-Comp, Inc.)

## Retropharyngeal Infections (Table 5)

### Overview

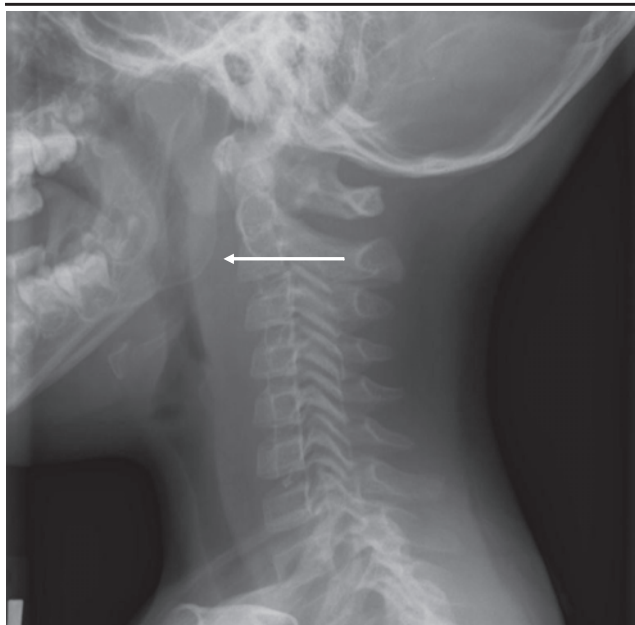A retropharyngeal infection, ranging from cellulitis to frank abscess formation,<sup>29</sup> occurs in the normally sterile retropharyngeal space. When not infected, this space is occupied by loose connective tissue and

lymph nodes which drain from head and neck structures (such as the nasopharynx, adenoids, posterior paranasal sinuses, middle ear, and eustachian tube). There are two ways by which a retropharyngeal abscess can develop: lymphatic spread of infection (the most common) or direct inoculation from trauma or foreign body. These infections occur more commonly in young children; most occur in patients less than six years of age, with a peak incidence of three years of age.<sup>15,65-67</sup> The predilection of this disease to develop in younger patients is thought to be due to the fact that retropharyngeal lymph nodes are prominent in young children and then undergo progressive involution and atrophy with time.<sup>25</sup>

Initially, patients present with vague signs and symptoms (such as fever and odynophagia) for several days. Subsequently, they develop high fever, drooling, poor feeding, neck stiffness and swelling, and torticollis<sup>16,29</sup> caused by muscular irritation from the infectious tissue.<sup>68</sup> In 2003, a study of 64 patients with retropharyngeal infections found that the most common chief complaints were neck pain (38%), fever (17%), sore throat (17%), neck mass (16%), and respiratory distress or stridor (5%). Almost half of the patients had limitation of neck extension, 37% had torticollis, and 13% had limitation of neck flexion. Stridor was a rare finding in contradiction to earlier reports and text book descriptions.<sup>15</sup>

Physical examination findings include midline

**Figure 4. Lateral XR Showing Retropharyngeal Abscess**



Note the widening of the prevertebral soft tissue spaces at the level of the upper cervical vertebrae

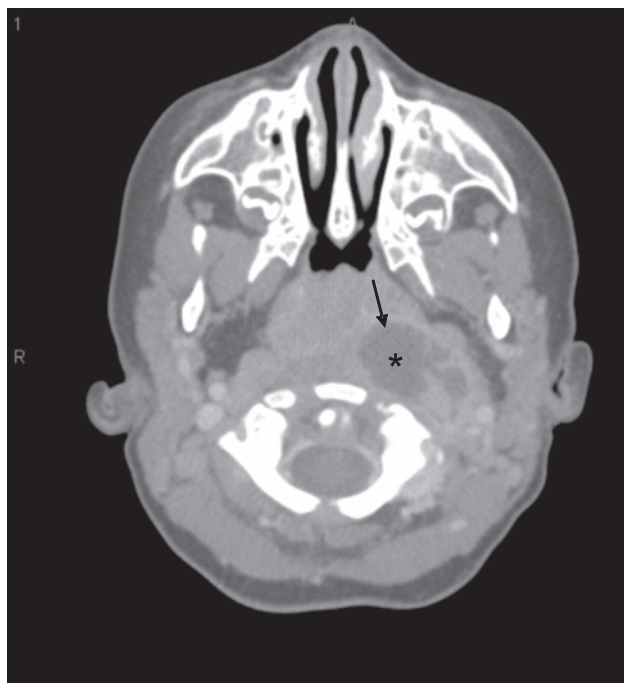
Reprinted with permission from: [http://rad.usuhs.edu/medpix/medpix.html?mode=caption\\_search&srchstr=Retropharyngeal+AND+Abscess&srch%20type=any&action=search](http://rad.usuhs.edu/medpix/medpix.html?mode=caption_search&srchstr=Retropharyngeal+AND+Abscess&srch%20type=any&action=search)

fullness of the oropharynx, although this can be difficult to appreciate. Causative organisms include *Staphylococcus aureus*, various streptococcal species, and anaerobes.<sup>69</sup> Complications from retropharyngeal infections include airway obstruction, aspiration pneumonia from rupture into the oropharynx, extension of infections to adjacent structures or compartments, sepsis, abscess recurrence,<sup>29,70</sup> and mediastinitis.

### Diagnosis

The lateral soft tissue neck radiograph is a good initial screening study for retropharyngeal infections, see **Figure 4**.<sup>29</sup> When the radiograph is performed correctly, increased thickness of the pre-vertebral soft tissue indicates the presence of a retropharyngeal infection. The radiograph should be taken on inspiration, and the neck must be in extension, as a film taken in end-expiration or a neutral or flexion view may result in a falsely widened retropharyngeal space. The diagnosis of retropharyngeal cellulitis or abscess is suggested when the retropharyngeal space at the level of C2 is twice the diameter of the vertebral body. This criterion has a sensitivity of nearly 90%.<sup>65</sup> Other authors have cited a prevertebral soft tissue swelling of greater than 7 mm at the level of the second cervical vertebra or greater than 14 mm at the level of the sixth cervical vertebra as concern for

**Figure 5. Contrast-Enhanced CT Scan Showing Retropharyngeal Abscess**

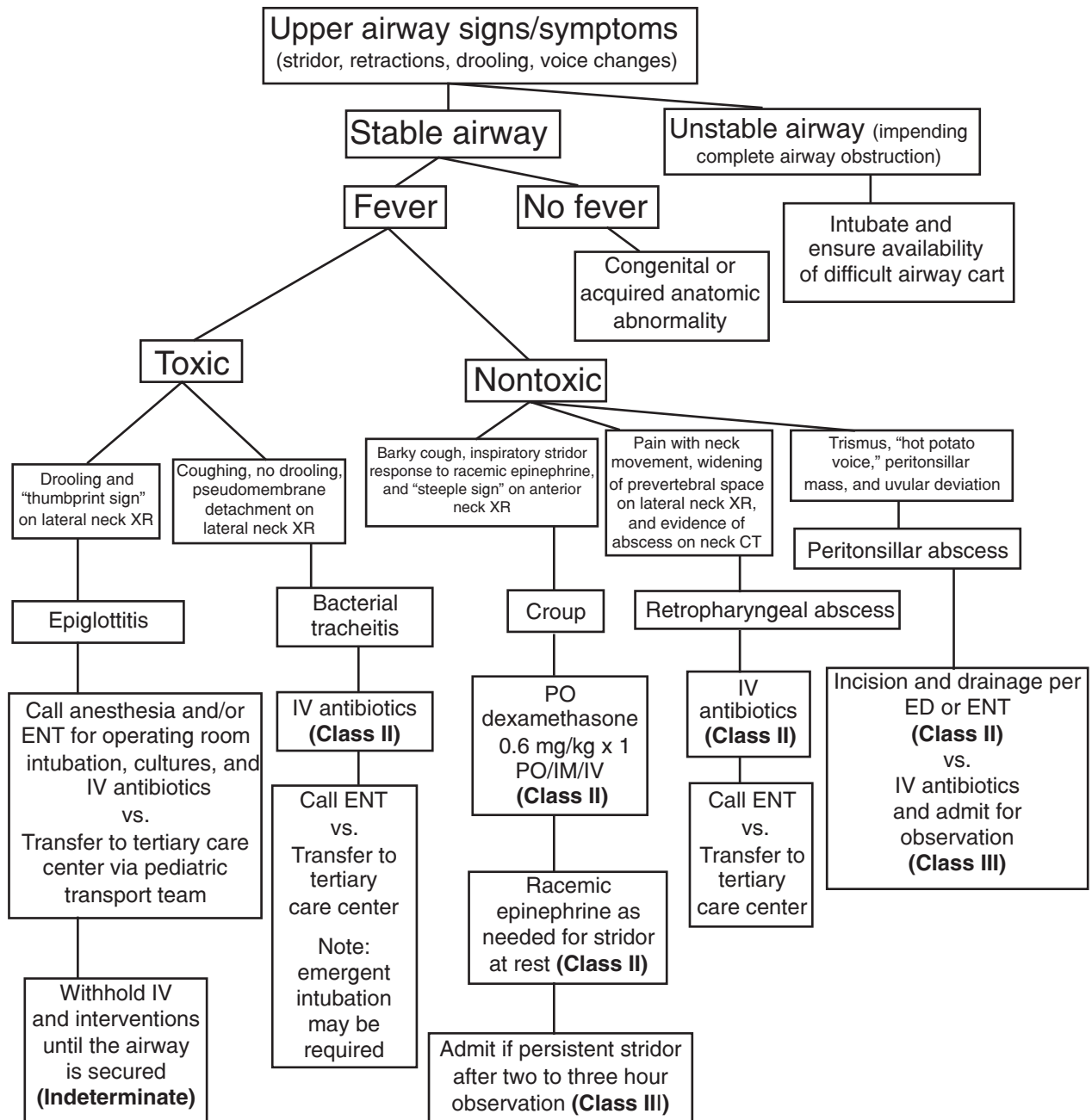


Note the left sided abscess shown by asterisk within rim-enhancing (arrow).

Reprinted with permission from *Pediatric Otolaryngology: Requisites in Pediatrics*. Figure 10-8. Pg 148, Copyright Elsevier 2007.



# Clinical Pathway: Approach To The Child With Upper Airway Distress



The **evidence for recommendations** is graded using the following scale. For complete definitions, see back page. **Class I:** Definitely recommended. Definitive, excellent evidence provides support. **Class II:** Acceptable and useful. Good evidence provides support. **Class III:** May be acceptable, possibly useful. Fair-to-good evidence provides support. **Indeterminate:** Continuing area of research.

*This clinical pathway is intended to supplement, rather than substitute for, professional judgment and may be changed depending upon a patient's individual needs. Failure to comply with this pathway does not represent a breach of the standard of care.*

Copyright © 2007 EB Practice, LLC. 1-800-249-5770. No part of this publication may be reproduced in any format without written consent of EB Practice, LLC.

widening of the retropharyngeal space and for infection.<sup>29</sup> The specificity of this finding is reported as 100%, with a sensitivity of 80-88%.<sup>72,73</sup> Other findings indicative of retropharyngeal infection are the presence of gas or air fluid levels within the retropharyngeal space, the presence of a foreign body in the airway, and the loss of normal cervical lordosis.<sup>25</sup>

If the diagnosis of retropharyngeal abscess is considered after suggestive plain radiography or by strong clinical suspicion, computed axial tomography (CT) with contrast should be used to confirm the diagnosis,<sup>66</sup> see **Figure 5**. CT is useful in defining the precise anatomical extension of the infection and in differentiating a true abscess from a cellulitis.<sup>25</sup> Sensitivity of the CT for the detection of retropharyngeal abscess is reported to be 43-100%, with a specificity of 57-88%.<sup>66,72,73</sup> Some authors have advocated for ultrasonography of the neck as a sensitive, non-irradiating alternative to CT;<sup>22,23,65</sup> however, no studies have been undertaken evaluating the use of ultrasound by emergency physicians for diagnosing retropharyngeal infections.

### Treatment

Traditional management of retropharyngeal infections included surgical drainage; however, more recent evidence suggests that many patients may be managed with early administration of intravenous antibiotics alone.<sup>15,65,73-75</sup> A retrospective series of 14 pediatric patients with deep neck infections (retropharyngeal included) described eight patients, seven of whom were treated successfully with antibiotic therapy alone. Despite the success in these cases, there have been no trials evaluating treatment with and without drainage, and conservative management alone has not, as of yet, been adopted as the standard of care in the management of retropharyngeal abscesses.

Empiric antibiotics (**Table 8**) should adequately cover gram positive and anaerobic organisms. A sample regimen may include clindamycin or ampicillin/sulbactam. If antibiotic therapy fails, drainage of the abscess is indicated. All patients with concerns for a retropharyngeal space infection should be admitted to the hospital and monitored for signs of respiratory compromise.

## Peritonsillar Infections (Table 5)

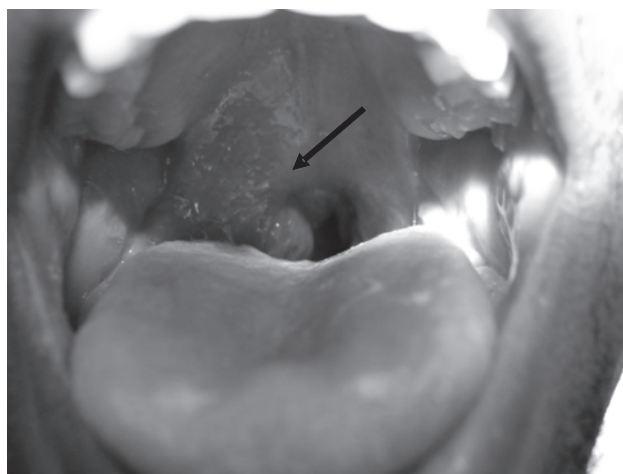
### Overview

Peritonsillar infections are the most common deep neck infections in adults and children.<sup>76,77</sup> Like retropharyngeal infections, they may range in scope from cellulitis (without any evidence of pus) to

phlegmon or pyogenic cellulitis (a localized infection which cannot be drained) to a frank abscess.<sup>76,78</sup> All represent an extension of infection from the tonsils<sup>64</sup> and involve the space surrounding the palatine tonsils.<sup>76,78</sup> Peritonsillar infections are more common in adolescents and adults than in younger children.<sup>74</sup> These infections are typically polymicrobial and causes include both aerobic and anaerobic bacteria.<sup>46,74</sup> *Streptococcus* species are the most common organisms cultured<sup>79</sup> and group A beta-hemolytic *streptococcus* (GABHS) is isolated in approximately one-third of cases.<sup>74</sup>

Symptoms of a peritonsillar infection include several days of fever, poor oral intake secondary to odynophagia, drooling, and a "hot potato voice."<sup>21,64,74,80</sup> Otolgia and neck pain ipsilateral to the side of the abscess may also be present. Trismus is a strong indicator of a peritonsillar abscess.<sup>81</sup> Examination of the oropharynx often reveals an erythematous bulging of the soft palate above the tonsil and uvular deviation away from the infected side, see **Figure 6**.

**Figure 6. Peritonsillar Abscess In An Adolescent Male**



Note the soft tissue mass in the right oropharynx (arrow).

Reprinted with permission from The Children's Hospital of Philadelphia.

Complications of peritonsillar infections include airway obstruction from the abscess itself or from rupture into the airway, mediastinitis, sepsis, and Lemierre's syndrome (an anaerobic suppurative thrombophlebitis of the internal jugular vein).<sup>76,82,83</sup>

### Diagnosis

The diagnosis is typically made clinically; however, some radiologic studies may be helpful in making the distinction between abscess and cellulitis.<sup>84</sup> Furthermore, imaging should be considered for unusual presentations or for persistent symptoms

despite needle aspiration or surgical drainage. CT with contrast has been the traditional imaging choice (Table 7); however, some authors have advocated ultrasonography of the neck as a more favorable choice, as it is inexpensive and lacks the radiation exposure conferred by CT. In 2003, the use of intraoral ultrasound by emergency medicine physicians to aid in the diagnosis of peritonsillar abscess versus cellulitis was first described.<sup>20</sup> In this series of six patients, ultrasound was correct in making the diagnosis of abscess and cellulitis in all patients. A study in 2005 evaluated the use of intraoral ultrasound for the diagnosis and management of peritonsillar infections in adults in the ED.<sup>21</sup> Ultrasound was 100% sensitive and 89% specific whereas clinical examination was 78% sensitive and 50% specific. Ultrasound had a positive predictive value of 97% and a negative predictive value of 100%.

### Treatment

Similar to retropharyngeal infections, treatment of peritonsillar infections includes antibiotic therapy with or without incision and drainage. Appropriate empiric antibiotic options include ampicillin/sulbactam or clindamycin, see Table 8. In the setting of abscess drainage, the choice of antibiotics has been shown to have no effect on outcome when broad-spectrum antibiotics were compared to intravenous penicillin alone.<sup>85</sup> Some authors advocate a conservative approach to the treatment of peritonsillar abscesses, eliminating the need for surgical drainage. A 2006 study of 98 children greater than nine years of age (most were greater than 15 years of age) evaluated a protocol of outpatient management consisting of hydration, analgesia, antibiotics, and high dose steroids.<sup>19</sup> Only four patients subsequently required post-treatment drainage.

The use of steroids as adjunctive treatment has been a controversial topic, and there was no evidence to support or refute any additive benefit in the management of peritonsillar infections until recently. A randomized, controlled trial of a single dose of intravenous methylprednisolone (2-3 mg/kg, max 250 mg) in 62 adult patients resulted in improvement of pain, fever, and edema and a reduction in the duration of hospitalization.<sup>77</sup> Of note, all of the patients in the study underwent incision and drainage prior to being treated with steroids.

Some physicians fear the use of sedation when performing incision and drainage for peritonsillar infection in the ED, and this may account for the high rate of operative management in some centers. A case series of 83 children diagnosed with peritonsillar abscess found that about half of patients required

treatment in the operating room.<sup>76</sup> Recent studies have found procedural sedation to be safe and effective<sup>86-88</sup> for this procedure in the ED. A review of 42 patients who underwent sedation for peritonsillar abscess incision and drainage in the ED of a children's hospital found sedation to be safe. The only complication reported was vomiting in one patient. The majority of the sedations (86%) used ketamine and midazolam.<sup>88</sup> Another study at the same institution compared patients who were sedated and those who were not sedated in the ED for peritonsillar abscess drainage. The procedure was more successful in the sedated group, and the sedation was found to be safe, with only one reported complication (oxygen desaturation to 88% which resolved with stimulation).<sup>86</sup> No one in the sedation group required a secondary procedure under general anesthesia.

## Epiglottitis (Table 5)

### Overview

Epiglottitis is a life-threatening airway emergency.<sup>25</sup> Also referred to as supraglottitis, it is characterized by a diffuse inflammatory process of the supraglottic structures in addition to the epiglottis.<sup>25</sup> Epiglottitis can occur at any age, but it is classically described in children between two and eight years of age.<sup>89-93</sup>

*Haemophilus influenzae* type B is still the most common causative organism;<sup>94</sup> however, the incidence of epiglottitis in children less than five years of age has dramatically decreased following the introduction of the *Haemophilus influenzae* type B vaccine.<sup>95</sup> Many other organisms have now been implicated, such as *Streptococcus*, *Staphylococci*, *Candida albicans*,<sup>4,5,96</sup> viruses,<sup>97</sup> pneumococci,<sup>98</sup> *Klebsiella*,<sup>99</sup> and *Pseudomonas*.<sup>100</sup>

The classic presentation in children with epiglottitis is high fever, irritability, throat pain, and drooling.<sup>28</sup> A spontaneous cough is usually absent. Symptoms rapidly progress, and the hallmark of illness is the toxic appearance of the child in conjunction with the above symptoms. Children will often prefer to rest in the tripod position (upright sitting position leaning forward and supported by both hands with the chin up and mouth open) in order to maximize airway diameter and air entry.<sup>25,29</sup> The classic "4 Ds" of epiglottitis are: drooling, dyspnea, dysphagia, and dysphonia.<sup>101</sup> Although epiglottitis is considered in the differential diagnosis of a child with stridor, stridor is actually a late finding and indicates impending complete airway obstruction.<sup>25,28</sup> Clinical features associated with a higher likelihood of airway obstruction include respiratory distress, stridor, drooling, and a rapid progression of symptoms.<sup>102</sup> Despite the

advent of widespread immunization, an up-to-date immunization history does not exclude the possibility of HIB-related epiglottitis in a child with a clinically consistent presentation. There have been a number of cases reported in immunized patients.<sup>4,5,96,91</sup> Complications from epiglottitis include deep neck space infections, recurrent illness, and vocal cord granulomas.<sup>1</sup>

### Diagnosis

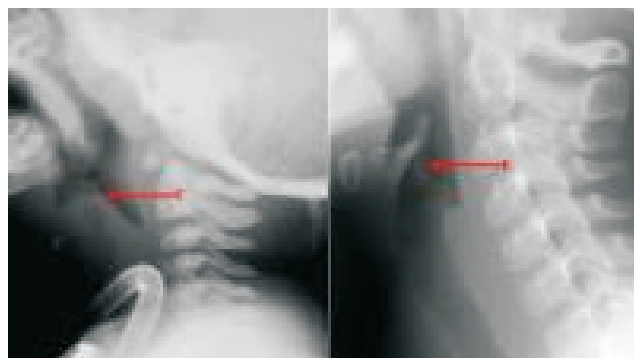
If the diagnosis is in question and the patient is stable, a lateral radiograph of the soft tissues of the neck may show the classic finding of a "thumbprint sign"<sup>1,25</sup> (a round and thick epiglottis with the loss of the vallecular air space)<sup>28</sup> and thickening of the aryepiglottic folds,<sup>28</sup> see **Table 7** and **Figure 7**. Confirmatory diagnosis of epiglottitis is made upon direct visualization of the supraglottic region, including the epiglottis. This should only be attempted in the operating room under controlled conditions. Never attempt visualization in the emergency department setting.

### Treatment

If the diagnosis is suspected, keep the child calm and comfortable. Abandon intravenous line placement, administration of antibiotics, and other interventions, see **Table 4 on page 4**. Arrange for immediate transfer to a facility capable of diagnosing and managing complete airway obstruction due to epiglottitis if such personnel are not available. A pediatric otolaryngologist and/or anesthesiologist should be the first choice consultants in the care of such patients. A physician capable of advanced airway management should accompany the child at all times until s/he is completely stabilized.

Once the patient is stabilized in the operating room, cultures from the airway and blood may be

**Figure 7. Normal Epiglottis Contrasted With Thickened Epiglottis**



Reprinted with permission from eMedicine.com, 2007. Available at <http://www.emedicine.com/radio/topic263.htm>

obtained and an intravenous line inserted, followed by antibiotic administration. Until cultures are available, treat with broad-spectrum antibiotics effective against B-lactamase-producing HIB. Reasonable empiric choices include a second- or third-generation cephalosporin,<sup>29</sup> see **Table 8**.

Most patients with epiglottitis, particularly those in severe distress, will be intubated for airway protection; although, occasionally, the older patient may not require intubation and may be managed conservatively with supplemental oxygen, antibiotics, and very close monitoring in the intensive care setting.<sup>103</sup> Steroids are frequently administered for the management of airway inflammation; however, no controlled studies exist to justify this approach in epiglottitis.<sup>1</sup>

### Controversies/Cutting Edge

The literature on upper airway infections in children is deficient in several areas ripe for further investigation. Specifically, there is a lack of adequately powered randomized, controlled trials in children evaluating the efficacy of steroids for peritonsillar and retropharyngeal abscess. It is still unclear if a true abscess, in the case of peritonsillar and retropharyngeal abscess, can be managed adequately without the use of incision and drainage. The literature (specifically studying children) is scant, and more evidence is needed. With respect to croup, despite the numerous articles on steroid treatment, there has been no comparison of a single dose of dexamethasone with a two to three day regimen of prednisone. As immunizations become more universal, there may be a continued change in the epidemiology of many of these diseases, specifically epiglottitis and bacterial tracheitis. Microbial surveillance should be ongoing.

Ultrasound is a rapidly growing area in emergency medicine. Overall, the pediatric world has been slow to adopt its use. *For a comprehensive review of ultrasound, see the January 2007, Volume 4 Number 1 Pediatric Emergency Medicine Practice article titled, "Use*

### Key Points

- The changing epidemiology and bacteriology of epiglottitis does not remove it from the list of possible causes of fever and upper airway signs and symptoms in a child.
- Never convert a stable airway to an unstable airway by agitating a child or traumatizing the airway.
- Infectious upper airway obstructions can be fatal, no matter what the cause.
- Clinical presentations can be volatile and progress to respiratory failure quickly.
- Any presentation of croup (mild to severe) should be treated with steroids.

of *Bedside Ultrasound in the Pediatric ED*," at <http://pediatric.ebmedicine.net/redirect>. Intraoral and neck ultrasound for identifying and treating peritonsillar and retropharyngeal abscesses deserve further research in both the adult and pediatric realm.

## Disposition

A child with mild upper airway disease who has received appropriate treatment, is stable without evidence of respiratory compromise, and is capable of oral hydration without difficulty may be discharged home with close follow-up. Of the diseases discussed in this article, patients with croup or peritonsillar abscess have the highest potential for discharge from the emergency department if they meet discharge criteria. Criteria for discharge include:

- Absence of stridor at rest (if racemic epinephrine is given, observe for two to three hours for resumption of stridor and consider second treatment; if stridor persists after a second period of two to three hour observation, admit.)
- Absence of tachypnea, retractions
- Absence of hypoxemia
- Ability to take oral liquids without difficulty

The child with severe upper airway obstruction requires subspecialty services often available only at tertiary care children's hospitals. In these cases, arrange to transfer the child to such a facility after appropriate stabilization, regardless of the etiology

of the disease. Once the decision to transfer the patient is made, the transferring facility must determine the safest route for transfer (ground ambulance, air ambulance, or specialty hospital transport team). The referring physician may be uncomfortable definitively stabilizing the airway with intubation; in this case, attempts should be made to transfer the child to a hospital with a specially-trained transport team who could perform the procedure at the referring facility prior to transfer.

Bacterial tracheitis, epiglottitis, and retropharyngeal abscess require admission to the hospital for airway management, subspecialty consultation, and definitive treatment with intravenous antibiotics and possible surgical intervention.

## Case Conclusion

*The 15-month-old boy who came in with difficulty breathing and a deep, harsh quality to his cough was also found to have inspiratory stridor on examination. He was given a 0.6 mg/kg oral dose of dexamethasone and a 0.5 mL dose of racemic epinephrine. His stridor resolved and, after a three hour period of observation, he was discharged home. His parents were given instructions to follow-up the next day with his pediatrician and to return to the emergency department for stridor at rest or other signs of respiratory distress.*

## Risk Management Pitfalls

### 1. "Kids are just little adults."

The adult and pediatric airway are different and there are features that make a child more susceptible to airway obstruction even with a small degree of inflammation.

### 2. "It's probably just croup."

Always consider congenital/anatomic abnormalities as the cause of stridor in a young infant, particularly those without a fever or with recurrent stridor.

### 3. "Even though he looks distressed, there are no noises coming from the airway so he's probably ok."

Interpreting lack of stridor as no evidence of obstruction can be dangerous as it may indicate near complete airway obstruction.

### 4. "Let's lay him flat so I can get a better look and listen."

Always allow the child with severe upper airway obstruction to remain in a position of comfort.

### 5. "Let's use a tongue depressor to get a good look in the back of the throat."

Aggressively performing examination maneuvers in the oral cavity in an already agitated child with airway distress may lead to further airway edema and subsequent complete airway obstruction.

### 6. "Just get on the phone and transfer him to a tertiary care center; we are not equipped to handle this patient."

Before considering transfer of care, a child with impending respiratory failure or evidence of airway obstruction requires emergency stabilization first.

### 7. "It can't be epiglottitis; he's fully vaccinated."

Epiglottitis can be caused by many pathogens other than those for which there are vaccinations. Furthermore, vaccination does not guarantee immunity against *H. influenzae*, which is still the most common cause of epiglottitis.

### 8. "He has a fever and can't move his neck well; it can only be meningitis."

Retropharyngeal abscess should always be considered as a diagnosis in a young child with fever and neck pain.

### 9. "There is widening of the retropharyngeal space, so it must be a retropharyngeal abscess."

Take care when interpreting the lateral x-ray of a patient with suspected retropharyngeal abscess. In order to ensure accuracy, the neck must be in extension and the film obtained ideally on inspiration. Flexion or neutral position of the neck can lead to false positive interpretations.

## Summary

Pediatric upper airway infections are among the most common entities encountered by emergency physicians. Although they have overlapping symptoms and share common etiologic agents, each is a distinct clinical entity with characteristic presentation, course, and definitive management. The goals of emergency department care when a child presents with symptoms suggestive of an upper airway infectious process are to appropriately suspect life-threatening airway obstruction, refrain from inducing agitation, stabilize the airway, institute an appropriate diagnostic work-up, administer definitive therapy when warranted, and arrange a safe and appropriate disposition.

## References

Evidence-based medicine requires a critical appraisal of the literature based upon study methodology and number of subjects. Not all references are equally robust. The findings of a large, prospective, randomized, and blinded trial should carry more weight than a case report.

To help the reader judge the strength of each reference, pertinent information about the study, such as the type of study and the number of patients in the study, will be included in bold type following the reference, where available. In addition, the most informative references cited in this paper, as determined by the authors, will be noted by an asterisk (\*) next to the number of the reference.

- Shah RK, Roberson DW, Jones DT. Epiglottitis in the Hemophilus influenzae type b vaccine era: changing trends. *Laryngoscope* 2004;114:557-560. (Retrospective case series; 19 patients)
- Garpenholt O, Hugosson S, Fredlund H, et al. Epiglottitis in Sweden before and after introduction of vaccination against Haemophilus influenzae type b. *Pediatr Infect Dis J* 1999;18:490-493. (Retrospective population-based study)
- Faden H. The Dramatic change in the epidemiology of pediatric epiglottitis. *Pediatr Emerg Care* 2006;22:443-444. (Retrospective case series; 2 patients)
- Gonzalez Valdepena HWE, Rose E, Ungkanont K, et al. Epiglottitis and Haemophilus influenzae immunization: the Pittsburgh experience: a five-year review. *Pediatrics* 1995;96(3 Pt 1):424-427. (Retrospective case series; 28 patients)
- McEwan J, Giridharan W, Clarke RW, et al. Paediatric acute epiglottitis: not a disappearing entity. *Int J Pediatr Otorhinolaryngol* 2003;67:317-321. (Retrospective case series; 40 patients)
- Gorelick MH, Baker MD. Epiglottitis in children, 1979 through 1992. Effects of Haemophilus influenzae type b immunization. *Arch Pediatr Adolesc Med* 1994;148:47-50. (Retrospective case series; 142 patients)
- Price IM, Preyra I, Fernandes CM, et al. Adult epiglottitis: a five-year retrospective chart review in a major urban centre. *CJEM* 2005;7:387-390. (Retrospective case series; 54 patients)
- Wong EY, Berkowitz RG. Acute epiglottitis in adults: the Royal Melbourne Hospital experience. *Anz J Surg* 2001;71:740-743. (Retrospective case series; 17 patients)
- Frantz TD, Rasgon BM, Quesenberry CP. Acute epiglottitis in adults. Analysis of 129 cases. *JAMA* 1994;272:1358-1360. (Retrospective case series; 19 patients)
- MayoSmith MF, Hirsch PJ, Wodzinski SF, et al. Acute epiglottitis in adults. An eight-year experience in the state of Rhode Island. *N Engl J Med* 1986;314:1133-1139. (Retrospective case series; 56 patients)
- Solomon P, Weisbrod M, Irish JC, et al. Adult epiglottitis: the Toronto Hospital experience. *J Otolaryngol* 1998;27:332-336. (Retrospective case series; 57 patients)
- Wick F, Ballmer PE, Haller A. Acute epiglottitis in adults. *Swiss Med Wkly* 2002;132:541-547. (Retrospective case series; 12 patients)
- \* Scolnik D, Coates AL, Stephens D, et al. Controlled delivery of high vs low humidity vs mist therapy for croup in emergency departments. *JAMA* 2006;295:1274-1280. (Randomized controlled trial; 140 patients)
- \* Neto GM, Kentab O, Klassen TP, et al. A randomized controlled trial of mist in the acute treatment of moderate croup. *Acad Emerg Med* 2002;9:873-879. (Randomized controlled trial; 71 patients)
- Craig FW, Schunk JE. Retropharyngeal abscess in children: clinical presentation, utility of imaging, and current management. *Pediatrics* 2003;111:1394-1398. (Retrospective case series; 64 patients)
- Broughton RA. Nonsurgical management of deep neck infections in children. *Pediatr Infect Dis J* 1992;11:14-18. (Retrospective case series; 8 patients)
- Sichel JY, Dano I, Hocwald E, et al. Nonsurgical management of parapharyngeal space infections: a prospective study. *Laryngoscope* 2002;112:906-10 (Prospective clinical trial; 12 patients)
- Plaza Mayor G, Martinez-San Millan J, Martinez-Vidal A. Is conservative treatment of deep neck space infections appropriate? *Head Neck* 2001;23:126-133. (Prospective trial; 31 patients)
- Lamkin RH, Portt J. An outpatient medical treatment protocol for peritonsillar abscess. *Ear Nose Throat J* 2006;85:658-660. (Clinical trial; 98 patients)
- Blaivas M, Theodoro D, Duggal S. Ultrasound-guided drainage of peritonsillar abscess by the emergency physician. *Am J Emerg Med* 2003;21:155-158. (Case series; 6 patients)
- Lyon M, Blaivas M. Intraoral ultrasound in the diagnosis and treatment of suspected peritonsillar abscess in the emergency department. *Acad Emerg Med* 2005;12:85-88. (Retrospective case series; 43 patients)
- Chao HC, Chiu CH, Lin SJ, et al. Colour Doppler ultrasonography of retropharyngeal abscess. *J Otolaryngol* 1999;28:138-141. (Case series; 5 patients)
- Ben-Ami T, Yousefzadeh DK, Aramburo MJ. Pre-supplicative phase of retropharyngeal infection: contribution of ultrasonography in the diagnosis and treatment. *Pediatr Radiol* 1990;21:23-26. (Review article)
- Johnson RF, Stewart MG, Wright CC. An evidence-based review of the treatment of peritonsillar abscess. *Otolaryngol Head Neck Surg* 2003;128:332-343. (Review article)
- Rotta AT, Wiryawan B. Respiratory emergencies in children. *Respir Care* 2003;48(3):248-258. (Review Article)
- Loftis L. Acute infectious upper airway obstructions in children. *Semin Pediatr Infect Dis* 2006; 17(1):5-10. (Review Article)
- Savoy NB. Differentiating stridor in children at triage: It's not always croup. *J Emerg Nurs* 2005;31:503-505. (Review Article)
- Stroud RH, Friedman NR. An update on inflammatory disorders of the pediatric airway: Epiglottitis, croup, and tracheitis. *Am J Otolaryngol* 2001;22:268-275. (Review article)
- Rafei K, Lichenstein R. Airway infectious disease emergencies. *Pediatr Clin N Am* 2006;53:215-242. (Review Article)
- Leung A, Cho H. Diagnosis of stridor in children. *Am Fam Physician* 1999;60:2289-2296. (Review Article)
- Osmond M. Croup. *Clin Evid* 2002;8:319-328. (Review article)
- Baugh R, Gilmore BB. Infectious croup: A critical review. *Otolaryngol Head Neck Surg* 1986;95:40-46. (Review Article)
- Moore M, Little P. Humidified air inhalation for treating croup. *Cochrane Database of Systematic Reviews* 2006;(3). Art No:CD002870. DOI: 10.1002/14651858.CD002870.pub2. (Systematic review)
- Sparrow A, Geelhoed G. Prednisolone versus dexamethasone in croup: a randomized equivalence trial. *Arch Dis Child* 2006;91:580-583. (Randomized controlled trial; 133 patients)
- Cressman WR, Myer CM. Diagnosis and management of croup and epiglottitis. *Pediatr Clin North Am* 1994;41:265-276. (Review Article)
- Westley CR, Cotton EK, Brooks JG. Nebulized racemic epinephrine by IPPB for the treatment of croup. *Am J Dis Child* 1978;132:484-487. (Randomized controlled trial; 20 patients)
- Skolnik NS. Treatment of croup: a critical review. *Am J Dis Child* 1989;143:1045-1049. (Review article)
- Cunningham MJ. The old and new of acute laryngotracheal infections. *Clin Pediatr* 1992;31:56-64. (Review article)
- \*Kairys SW, Olmstead EM, O'Connor GT. Steroid treatment of laryngotracheitis: a meta-analysis of the evidence of randomized trials. *Pediatrics* 1989;83:683-693. (Systematic review)
- Ausejo M, Saenz A, Ba'Pham, et al. The effectiveness of glucocorticoids in treating croup: meta-analysis. *BMJ* 1999;319:595-600. (Systematic review)
- Geelhoed GC, Macdonald WBG. Oral and inhaled steroids in croup: a randomized, placebo-controlled trial. *Pediatric Pulmonology* 1995;20:355-361. (Randomized controlled trial; 80 patients)
- \*Bjornson CL, Klassen TP, Williamson J, et al. A randomized trial of a single dose of oral dexamethasone for mild croup. *N Engl J Med* 2004;351:1306-1313. (Randomized controlled trial; 720 patients)
- Sumboonanonanda A, Suwanjutha S, Sirinavin S. Randomized controlled trial of dexamethasone in infectious croup. *J Med Assoc Thai* 1997;80:262-265. (Randomized controlled trial; 32 patients)
- Rittichier KK, Ledwith CA. Outpatient treatment of moderate croup with dexamethasone: intramuscular versus oral dosing. *Pediatrics* 2000;106:1344-1348. (Randomized clinical trial; 277 patients)
- Chup-Uppakarn S, Sangsupawanich P. A randomized comparison of dexamethasone 0.15mg/kg versus 0.6mg/kg for the treatment of moderate to severe croup. *International Journal of Pediatric Otorhinolaryngology* 2007;71:473-477. (Randomized clinical trial; 41 patients)
- Martindale. *The complete drug reference*. 32nd edition. London: Pharmaceutical Press;1999:1037 (Textbook)
- Goodman LS, Limbird LE, Milinoff PB, et al, eds. *Goodman and Gilman's the pharmacological basis of therapeutics*. 9th ed. New York: McGraw-Hill; 1996. (Textbook)
- \* Johnson DW, Jacobson S, Edney P, et al. A comparison of nebulized budesonide, intramuscular dexamethasone, and placebo for moderately severe croup. *N Engl J Med* 1998;339:498-503. (Randomized controlled trial; 144 patients)
- Klassen TP, Watters LK, Feldman ME, et al. The efficacy of nebulized budesonide in dexamethasone-treated outpatients with croup. *Pediatrics* 1996;97:463-466. (Randomized controlled trial; 50 patients)
- \* Klassen TP, Craig WR, Moher D, et al. Nebulized budesonide and oral dexamethasone for treatment of croup: A randomized controlled trial. *JAMA* 1998;279:1629-1632. (Randomized controlled trial; 198 patients)
- \* Gardner HG, Powell KR, Roden VJ, et al. The evaluation of racemic epinephrine in the treatment of infectious croup. *Pediatrics* 1973;52:52-55. (Randomized controlled trial; 20 patients)
- Kristjansson S, Berg-Kelly K, Winso E. Inhalation of racemic adrenaline in the treatment of mild and moderately severe croup: clinical symptom score and oxygen saturation measurements for evaluation of treatment effects. *Acta Paediatr* 1994;83:1156-1160. (Randomized controlled trial; 54 patients)
- Landau LL, Geelhoed GC. Aerosolized steroids for croup. *N Engl J Med* 1994;331:322-323. (Editorial)
- Kelley PB, Simon JE. Racemic epinephrine use in croup and disposition. *Am J Emerg Med* 1992;10:181-183. (Retrospective case series; 50 patients)
- Predergast M, Jones JS, Hartman D. Racemic epinephrine in the treatment of laryngotracheitis: can we identify children for outpatient therapy? *Am J Emerg Med* 1994;12:613-616. (Prospective cohort study; 61 patients)
- Ledwith CA, She LM, Mauro RD. Safety and efficacy of nebulized racemic epinephrine in conjunction with oral dexamethasone and mist in the outpatient treatment of croup. *Ann Emerg Med* 1995;25:331-337. (Prospective interventional; 55 patients)
- McGee DL, Wald DA, Hinchliffe S. Helium-oxygen therapy in the emergency department. *J Emerg Med* 1997;15:291-296. (Review article)
- Yates RW, Doull IJ. A risk-benefit assessment of corticosteroids in the management of croup. *Drug Saf* 1997;16:48-55. (Review article)
- \*Hopkins A, Lahiri T, Salerno R, et al. Changing epidemiology of life-threatening

ing upper airway infections: the reemergence of bacterial tracheitis. *Pediatrics* 2006;118:1418-21. **(Retrospective case series; 107 patients)**

60. Marcos Alonso S, Molini Menchon N, Rodriguez Nunez A, et al. Bacterial tracheitis: an infectious cause of upper airway obstruction to be considered in children. *An Pediatr (Barc)* 2005;63:164-168. **(Retrospective case series; 12 patients)**

61. Liston SL, Gehr RC, Siegel LG, et al. Bacterial tracheitis. *Am J Dis Child* 1983; 137:764-767. **(Case series; 17 patients)**

62. Donaldson JD, Maltby CC. Bacterial tracheitis in children. *J Otolaryngol* 1989;18:101-104. **(Case series; 3 patients)**

63. Jones R, Santos JI, Overall JC. Bacterial tracheitis. *JAMA* 1979;242:721-726. **(Case series; 8 patients)**

64. Cummings CW, ed. *Otolaryngology-Head and Neck Surgery*. 3rd ed. St. Louis: Mosby;1998: 388-400. **(Textbook)**

65. Coulthard M, Isaacs D. Retropharyngeal abscess. *Arch Dis Child* 1991;66:1227-1230. **(Case series; 31 patients)**

66. Philpott CM, Selvadurai D, Banerjee AR. Paediatric retropharyngeal abscess. *J Laryngol Otol* 2004;118:919-926. **(Case report; 1 patient)**

67. Dawes LC, Bova R, Carter P. Retropharyngeal abscess in children. *ANZ J Surg* 2002;72:417-420. **(Retrospective case series; 21 cases)**

68. Fleisher G, Ludwig S, Henretig F, et al, eds. *Pediatric Emergency Medicine*. 5th ed. Philadelphia: Lippincott Williams & Wilkins; 2006:643-648. **(Textbook)**

69. Asmar BI. Bacteriology of retropharyngeal abscess in children. *Pediatr Infect Dis J* 1990;9:595-597. **(Retrospective case series)**

70. \*Craig, FW, Schunk JE. Retropharyngeal abscess in children: clinical presentation, utility of imaging, and current management. *Pediatrics* 2003;111:1394-1398. **(Retrospective case series; 64 patients)**

71. Ungkanont K, Yellon RF, Weissman JL, et al. Head and neck space infections in infants and children. *Otolaryngol Head Neck Surg* 1995;112:375-382. **(Retrospective case series; 117 patients)**

72. Daya H, Lo S, Papsin BC, et al. Retropharyngeal and parapharyngeal infections in children: the Toronto experience. *Int J Pediatr Otorhinolaryngol* 2005;69:81-86. **(Retrospective case series; 27 patients)**

73. Al-Sabah B, Bin Salleen H, Hagr A, et al. Retropharyngeal abscess in children: 10-year study. *J Otolaryngol* 2004;33:352-355. **(Retrospective case series; 68 patients)**

74. Brook I. Microbiology and management of peritonsillar, retropharyngeal, and parapharyngeal abscesses. *J Oral Maxillofac Surg* 2004;62:1545-1550. **(Review article)**

75. Dufour X, Gohler C, Bedier A, et al. Retropharyngeal and lateral pharyngeal abscess in children. *Ann Otolaryngol Chir Cervicofac* 2004;121:327-333. **(Retrospective case series; 5 patients)**

76. Schraff S, McGinn JD, Derkay CS. Peritonsillar abscess in children: a 10-year review of diagnosis and management. *Int J Pediatr Otorhinolaryngol* 2001;57:213-218. **(Retrospective case series; 83 patients)**

77. Ozbek C, Aygenc E, Unsal Tuna E, et al. Use of steroids in the treatment of peritonsillar abscess. *J Laryngol Otol* 2004;118:439-442. **(Randomized controlled trial; 62 patients)**

78. Licameli FR, Grillone GA. Inferior pole peritonsillar abscess. *Otolaryngol Head Neck Surg* 1998;118:95-99. **(Case report)**

79. Herzon FS. Peritonsillar abscess: incidence, current management practices, and a proposal for treatment guidelines. *Laryngoscope* 1995;105:1-17. **(Cohort study; 123 patients/National survey; 1460 respondents/Systematic review)**

80. Friedman NR, Mitchell RB, Pereira KD, et al. Peritonsillar abscess in early childhood: presentation and management. *Arch Otolaryngol Head Neck Surg* 1997;123:630-632. **(Retrospective case series; 7 patients)**

81. Suzhay G, Tewfik TL. Peritonsillar abscess or cellulitis? a clinical comparative paediatric study. *J Otolaryngol* 1998;27:206-212. **(Retrospective case series; 185 patients)**

82. Ramirez S, Hild TG, Rudolph CN, et al. Increased diagnosis of Lemierre syndrome and other *Fusobacterium necrophorum* infections at a children's hospital. *Pediatrics* 2003;112:E380. **(Retrospective case series; 14 patients)**

83. Matsuda A, Tanaka H, Kanaya T, et al. Peritonsillar abscess: a study of 724 cases in Japan. *Ear Nose Throat J* 2002;81:384-389. **(Retrospective case series; 724 patients)**

84. Scott PM, Loftus WK, Kew J, et al. Diagnosis of peritonsillar infections: a prospective study of ultrasound, computerized tomography and clinical diagnosis. *J Laryngol Otol* 1999;113:229-232. **(Prospective study; 14 patients)**

85. Kieff DA, Bhattacharyya N, Siegel NS, et al. Selection of antibiotics after incision and drainage of peritonsillar abscesses. *Otolaryngol Head Neck Surg* 1999;120:57-61. **(Retrospective case series; 103 patients)**

86. Suskind DL, Park J, Piccirilli JF, et al. Conscious sedation: a new approach for peritonsillar abscess drainage in the pediatric population. *Arch Otolaryngol Head Neck Surg* 1999;125:1197-1200. **(Retrospective case series; 52 patients)**

87. Bauer PW, Lieu JE, Suskind DL, et al. The safety of conscious sedation in peritonsillar abscess drainage. *Arch Otolaryngol Head Neck Surg* 2001; 127:1477-1480. **(Retrospective case series; 91 patients)**

88. Luhmann JD, Kennedy RM, McAllister JD, et al. *Pediatr Emerg Care* 2002; 18:1-3. **(Retrospective case series; 42 patients)**

89. Mauro RD, Poole SR, Lockhart CH. Differentiation of epiglottitis from laryngotracheitis in the child with stridor. *Am J Dis Child* 1988;142:621-626. **(Cross-sectional study; 155 patients)**

90. Rosenfeld RM, Fletcher MA, Marban SL. Acute epiglottitis in a newborn infant. *Pediatr Infect Dis J* 1992;11:594-595. **(Case report)**

91. Baines DB, Wark H, Overton JH. Acute epiglottitis in children. *Anaesth Intensive Care* 1985;13:25-28. **(Retrospective case series; 161 patients)**

92. Losek JD, Dewitz-Zink BA, Melzer-Lange M, et al. Epiglottitis: comparison of signs and symptoms in children less than 2 years old and older. *Am Emerg Med* 1990;19:55-58. **(Retrospective case series; 236 patients)**

93. Brilli RJ, Benzling G 3rd, Cotcamp DH. Epiglottitis in infants less than two years of age. *Pediatr Emerg Care* 1989;5:16-21. **(Retrospective case series; 41 patients)**

94. Senior BA, Radkowski D, MacArthur C, et al. Changing patterns in pediatric supraglottitis: A multi-institutional review, 1980-1992. *Laryngoscope* 1994;104:1314-1322. **(Retrospective case series; 252 patients)**

95. Progress toward eliminating *Haemophilus influenzae* type b disease among infants and children-United States, 1987-1997. *MMWR Morb Mortal Wkly Rep* 1998;47:993-998.

96. Wagle A, Jones RM. Acute epiglottitis despite vaccination with *Haemophilus influenzae* type b vaccine. *Pediatr Anaesth* 1999;9:549-550. **(Case report)**

97. Grattan-Smith T, Forer M, Kilham H, Gillis J. Viral supraglottitis. *J Pediatr* 1987;110:434-435. **(Case series; 2 patients)**

98. Crysdale WS, Sendi K. Evolution in the management of acute epiglottitis: a 10-year experience with 242 children. *Int Anesthesiol Clin* 1988;26:32-38. **(Retrospective case series; 242 patients)**

99. Murrage KJ, Janzen VD, Ruby RR. Epiglottitis: adult and pediatric comparisons. *J Otolaryngol* 1988;17:194-198. **(Retrospective case series)**

100. Lacroix J, Gauthier M, Lapointe N, et al. *Pseudomonas aeruginosa* supraglottitis in a six-month-old child with severe combined immunodeficiency syndrome. *Pediatr Infect Dis J* 1988;7:739-741. **(Case report)**

101. Blackstock D, Adderley RJ, Steward DJ. Epiglottitis in young infants. *Anesthesiology* 1987;67:97-100. **(Retrospective case series; 14 patients)**

102. Mayo-Smith MF, Spinale JW, Donskey CJ, et al. Acute epiglottitis: an 18-year experience in Rhode Island. *Chest* 1995;108:1640-1647. **(Retrospective case series; 407 patients)**

103. Loos GD. Pharyngitis, croup, and epiglottitis. *Prim Care* 1990;17:335-345. **(Review article)**

## CME Questions

- The most common cause of acute stridor in childhood is:**
  - Viral croup
  - Spasmodic croup
  - Retropharyngeal abscess
  - Epiglottitis
- Compared to children with viral croup, children with bacterial tracheitis generally:**
  - Are ill-appearing
  - Are younger
  - Respond to racemic epinephrine
  - Are not vaccinated
- An appropriate empiric antibiotic regimen for bacterial tracheitis would include any of the following except:**
  - Oxacillin
  - Vancomycin
  - Ampicillin/sulbactam
  - Cefotaxime
  - Ceftriaxone
- Appropriate disposition for the stable child with suspected bacterial tracheitis is:**
  - Home with oral antibiotics
  - Medical floor with IV antibiotics
  - Intensive care unit with IV antibiotics
  - Intensive care unit with IV antibiotics and mechanical ventilation
- A retropharyngeal abscess can develop from:**
  - Lymphatic spread
  - Direct inoculation
  - Bacteremia
  - A and B
  - B and C
- The most common complaint of a child with a retropharyngeal abscess is:**
  - Neck pain
  - Fever
  - Vomiting
  - Sore throat
- A widened retropharyngeal space is indicative of a retropharyngeal abscess only when an x-ray is obtained in:**
  - Flexion
  - Extension
  - Neutral
  - Oblique
- The most common deep neck infection in children is:**
  - Retropharyngeal abscess
  - Cervical adenitis
  - Peritonsillar abscess
  - Parapharyngeal abscess

9. Which of the following is a strong clinical indicator of a peritonsillar abscess?

- a. Drooling
- b. Voice changes (“hot potato voice”)
- c. Exudative pharyngitis
- d. Trismus
- e. Uvular deviation toward the affected side

10. The diagnosis of a peritonsillar abscess is usually made by:

- a. Clinical exam alone
- b. Plain radiography of the neck
- c. CT scan
- d. A and C

11. Treatment of a peritonsillar infection must include:

- a. Incision and drainage
- b. Antibiotics
- c. Steroids
- d. A and B

12. The #1 cause of epiglottitis in the post-*H. influenzae* vaccine era is:

- a. *S. pneumoniae*
- b. *S. aureus*
- c. *H. influenzae*
- d. *E. coli*

## Class Of Evidence Definitions

Each action in the clinical pathways section of *Pediatric Emergency Medicine Practice* receives a score based on the following definitions.

### Class I

- Always acceptable, safe
- Definitely useful
- Proven in both efficacy and effectiveness

### Level Of Evidence:

- One or more large prospective studies are present (with rare exceptions)
- High-quality meta-analyses
- Study results consistently positive and compelling

### Class II

- Safe, acceptable
- Probably useful

### Level Of Evidence:

- Generally higher levels of evidence
- Non-randomized or retrospective studies: historic, cohort, or case-control studies
- Less robust RCTs
- Results consistently positive

### Class III

- May be acceptable
- Possibly useful
- Considered optional or alternative treatments

### Level Of Evidence:

- Generally lower or intermediate

### levels of evidence

- Case series, animal studies, consensus panels
- Occasionally positive results

### Indeterminate

- Continuing area of research
- No recommendations until further research

### Level of Evidence:

- Evidence not available
- Higher studies in progress
- Results inconsistent, contradictory
- Results not compelling

Significantly modified from The Emergency Cardiovascular Care Committees of the American Heart Association and representatives from the resuscitation councils of ILCOR: How to Develop Evidence-Based Guidelines for Emergency Cardiac Care: Quality of Evidence and Classes of Recommendations; also: Anonymous. Guidelines for cardiopulmonary resuscitation and emergency cardiac care. Emergency Cardiac Care Committee and Subcommittees, American Heart Association. Part IX. Ensuring effectiveness of community-wide emergency cardiac care. *JAMA* 1992;268(16):2289-2295.

## Physician CME Information

**Accreditation:** This activity has been planned and implemented in accordance with the Essentials and Standards of the Accreditation Council for Continuing Medical Education (ACCME) through the joint sponsorship of Mount Sinai School of Medicine and *Pediatric Emergency Medicine Practice*. The Mount Sinai School of Medicine is accredited by the ACCME to provide continuing medical education for physicians.

**Credit Designation:** The Mount Sinai School of Medicine designates this educational activity for a maximum of 48 *AMA PRA Category 1 Credit(s)*<sup>™</sup> per year. Physicians should only claim credit commensurate with the extent of their participation in the activity.

Credit may be obtained by reading each issue and completing the printed post-tests administered in June and December or online single-issue post-tests administered at EBMedicine.net.

**Target Audience:** This enduring material is designed for emergency medicine physicians.

**Needs Assessment:** The need for this educational activity was determined by a survey of medical staff, including the editorial board of this publication; review of morbidity and mortality data from the CDC, AHA, NCHS, and ACEP; and evaluation of prior activities for emergency physicians.

**Date of Original Release:** This issue of *Pediatric Emergency Medicine Practice* was published November 1, 2007. **This activity is eligible for CME credit through November 1, 2010.** The latest review of this material was September 14, 2007.

**Discussion of Investigational Information:** As part of the newsletter, faculty may be presenting investigational information about pharmaceutical products that is outside Food and Drug Administration approved labeling. Information presented as part of this activity is intended solely as continuing medical education and is not intended to promote off-label use of any pharmaceutical product. Disclosure of Off-Label Usage: This issue of *Pediatric Emergency Medicine Practice* discusses no off-label use of any pharmaceutical product.

**Faculty Disclosure:** It is the policy of Mount Sinai School of Medicine to ensure objectivity, balance, independence, transparency, and scientific rigor in all CME-sponsored educational activities. All faculty participating in the planning or implementation of a sponsored activity are expected to disclose to the audience any relevant financial relationships and to assist in resolving any conflict of interest that may arise from the relationship. Presenters must also make a meaningful disclosure to the audience of their discussions of unlabeled or unapproved drugs or devices.

In compliance with all ACCME Essentials, Standards, and Guidelines, all faculty for this CME activity were asked to complete a full disclosure statement. The information received is as follows: Dr. Baren, Dr. Marin, Dr. Sharieff, and Dr. Toscano report no significant financial interest or other relationship with the manufacturer(s) of any commercial product(s) discussed in this educational presentation.

**ACEP Accreditation:** *Pediatric Emergency Medicine Practice* is also approved by the American College of Emergency Physicians for 48 hours of ACEP Category 1 credit per annual subscription.

**AAP Accreditation:** This continuing medical education activity has been reviewed by the American Academy of Pediatrics and is acceptable for up to 44 AAP credits. These credits can be applied toward the AAP CME/CPD Award available to Fellows and Candidate Fellows of the American Academy of Pediatrics.

### Method of Participation:

**Print Subscription Semester Program:** Paid subscribers with current and valid licenses in the United States who read all CME articles during each *Pediatric Emergency Medicine Practice* six-month testing period, complete the post-test and the CME Evaluation Form distributed with the December and June issues, and return it according to the published instructions are eligible for up to 4 hours of CME credit for each issue. You must complete both the post test and CME Evaluation Form to receive credit. Results will be kept confidential. CME certificates will be delivered to each participant scoring higher than 70%.

**Online Single-Issue Program:** Current, paid subscribers with current and valid licenses in the United States who read this *Pediatric Emergency Medicine Practice* CME article and complete the online post-test and CME Evaluation Form at EBMedicine.net are eligible for up to 4 hours of Category 1 credit toward the AMA Physician's Recognition Award (PRA). You must complete both the post-test and CME Evaluation Form to receive credit. Results will be kept confidential. CME certificates may be printed directly from the Web site to each participant scoring higher than 70%.

**Hardware/Software Requirements:** You will need a Macintosh or PC with internet capabilities to access the website. Adobe reader is required to download archived articles.

**Pediatric Emergency Medicine Practice is not affiliated with any pharmaceutical firm or medical device manufacturer.**

**CEO: Robert Williford President and Publisher: Stephanie Williford Director of Member Services: Liz Alvarez**

Direct all editorial or subscription-related questions to EB Medicine: 1-800-249-5770 • Fax: 1-770-500-1316 • Non-U.S. subscribers, call: 1-678-366-7933

EB Medicine • 5550 Triangle Pkwy, STE 150 • Norcross, GA 30092

E-mail: [ebm@ebmedicine.net](mailto:ebm@ebmedicine.net) • Web Site: [EBMedicine.net](http://EBMedicine.net)

*Pediatric Emergency Medicine Practice* (ISSN Print: 1549-9650, ISSN Online: 1549-9669) is published monthly (12 times per year) by EB Practice, 5550 Triangle Pkwy, Ste. 150, Norcross, GA 30092. Opinions expressed are not necessarily those of this publication. Mention of products or services does not constitute endorsement. This publication is intended as a general guide and is intended to supplement, rather than substitute for, professional judgment. It covers a highly technical and complex subject and should not be used for making specific medical decisions. The materials contained herein are not intended to establish policy, procedure, or standard of care. *Pediatric Emergency Medicine Practice* is a trademark of EB Practice, LLC. Copyright © 2007 EB Practice, LLC. All rights reserved. No part of this publication may be reproduced in any format without written consent of EB Practice, LLC. Individual subscription price: \$299, Institutional/library/hospital price: \$699, U.S. funds. (Call for international shipping prices.)